

# Sequential Treatment with Triple Combination Cream and Intense Pulsed Light is More Efficacious than Sequential Treatment with an Inactive (Control) Cream and Intense Pulsed Light in Patients with Moderate to Severe Melasma

MITCHEL P. GOLDMAN, MD,\* MICHAEL H. GOLD, MD,<sup>†</sup> MELANIE D. PALM, MD,\*  
LUZ E. COLÓN, MS, CCRC, CCRA,<sup>‡</sup> NORMAN PRESTON, PHD,<sup>‡</sup> LORI A. JOHNSON, PHD,<sup>‡</sup> AND  
RONALD W. GOTTSCHALK, MD, FRCPC<sup>‡</sup>

**BACKGROUND** Triple combination (TC) cream is a stable combination of fluocinolone acetonide 0.01%, hydroquinone 4%, and tretinoin 0.05% and is currently the only hydroquinone-containing drug approved by the Food and Drug Administration for the treatment of melasma.

**OBJECTIVE** To evaluate the safety and efficacy of TC cream when used sequentially with intense pulsed light (IPL) treatments in patients with moderate to severe melasma.

**MATERIALS & METHODS** This was a 10-week, split-face study in which 56 patients with symmetrical melasma lesions were treated with TC cream on one side of the face and an inactive control cream on the other side of the face. Patients also had two IPL treatments at weeks 2 and 6. (Topical treatment was suspended during IPL treatments  $\pm$  1 day.)

**RESULTS** Melasma severity was significantly less with TC cream and IPL than with inactive cream and IPL at weeks 6 ( $p=.007$ ) and 10 ( $p=.002$ ). Improvement in melasma was greater with TC cream and IPL than with inactive cream and IPL according to investigator and patient evaluations at weeks 6 and 10 ( $p<.001$  for both time points). Treatment with TC cream and IPL was well tolerated.

**CONCLUSION** The results of this study suggest that TC cream and IPL treatment is an effective and safe treatment option for patients with melasma.

*This study was supported by Galderma Laboratories, LP. Dr. Gold performs research for Galderma. Dr. Gold is a consultant to Lumenis and speaks and performs research on their behalf. Dr. Palm is a speaker and trainer for Lumenis. Luz Colon, Norman Preston, Lori Johnson, and Ronald Gottschalk are employees of Galderma.*

Melasma is a skin disorder of hyperpigmentation that usually involves areas of the face and neck.<sup>1</sup> This disease has historically been underdiagnosed and undertreated because it is considered a cosmetic nuisance more often than a skin disorder.<sup>2</sup> Melasma is primarily a disease of women, and it has been reported that 5 million to 6 million American women have melasma.<sup>1</sup> The exact etiology of melasma is unknown, but some suspected etiologic factors include genetic predisposition, ultraviolet radiation exposure, cosmetics, phototoxic drugs, and antiseizure medications.<sup>3,4</sup> In addition to these, hormonal changes and imbalances have been sus-

pected in the pathogenesis of melasma according to anecdotal case reports and because of the tendency for melasma to manifest during pregnancy or other circumstances of hormonal flux such as hormone replacement therapy or oral contraception.<sup>5-10</sup> Also, sunlight has been identified as the primary cause of the exacerbation of melasma.<sup>11</sup> Thus, minimizing sun exposure, in conjunction with the daily use of a broad-spectrum sunscreen, is important for patients with melasma.<sup>12,13</sup>

Melasma is often refractory to treatment.<sup>14,15</sup>

Treatment approaches include drugs or procedures

\*Department of Dermatology, University of California at San Diego, San Diego, California; <sup>†</sup>Gold Skin Care Center, Tennessee Clinical Research Center, Nashville, Tennessee; <sup>‡</sup>Galderma Laboratories, L.P., Fort Worth, Texas

used individually, a regimen with a combination of drugs, or a combination of a drug with a dermatologic procedure such as a chemical peel, microdermabrasion, intense pulsed light (IPL), or another laser treatment.<sup>2,12,16-18</sup> Evidence from a pilot study suggests that significant improvements (65% clear or almost clear,  $p < .001$ ) in melasma can be achieved using a triple combination (TC) cream containing fluocinolone acetonide 0.01%, hydroquinone 4%, and tretinoin 0.05% with glycolic acid peels.<sup>17</sup>

Treatment of melasma with TC cream has resulted in 77% of patients being clear or almost clear after 8 weeks of treatment.<sup>19</sup> Additionally, two studies have reported efficacy of TC cream with use for 12 months. In one study, 80% of patients were clear or almost clear of melasma and, in the other, 90% of patients were clear or almost clear of melasma after 12 months of treatment.<sup>20,21</sup>

The Food and Drug Administration has approved IPL treatment that encompasses a range of wavelengths of light with a selection of cut-off filters to treat a variety of vascular and pigmented lesions for treating melasma.<sup>22-25</sup> During treatment, melanin absorbs the IPL energy, leading to fragmentation, phagocytosis of the pigment, and transfer of the absorbed heat energy to destroy the melanin-containing epidermal cells.<sup>26</sup> A recent study of 38 patients who underwent IPL treatment for melasma reported excellent response in 47% of patients and good response in 29%.<sup>27</sup>

## Patients and Methods

A 10-week, split-face, randomized, evaluator-blinded, open-label study was designed to compare the safety and efficacy of TC cream (Tri-Luma Cream, Galderma Laboratories, L.P., Fort Worth, TX) with that of an inactive control cream when used sequentially with a series of two IPL treatments (Lumenis One, Lumenis, Santa Clara, CA) in patients with moderate to severe melasma. Male or female patients of any race, aged 18 to 74 and with Fitzpatrick skin types I to IV were eligible for

enrollment. Patients were required to avoid prolonged sun exposure to the face for the duration of the study and to use appropriate sun avoidance techniques including the use of sun block (SPF 45, Neutrogena Corp., Los Angeles, CA), which was provided.

A randomization scheme determined which side of the face was treated with TC cream; inactive cream was applied to the contralateral side of the face. The entire face was treated with IPL. The IPL treatment parameters included a 560-nm cut-off filter, a double-pulse technique with pulses of 3.0 to 3.5 ms each, and a delay time that was matched to skin type. (Patients with Fitzpatrick skin type I were treated with a pulse delay of 10 ms, type II with a delay of 20 ms, and types III and IV with a delay of 30 ms.) The fluence varied from 14 to 18 J/cm<sup>2</sup> so that mild darkening of the pigmented areas occurred without production of an erythematous footprint. The second IPL treatment typically employed a fluence 10% higher than the first IPL treatment. Treatment visits were at baseline and weeks 2, 6, and 10, with IPL treatments at weeks 2 and 6. Patients were instructed to apply TC and inactive cream once daily at night for 2 weeks before the first IPL treatment. They discontinued TC cream and inactive cream applications 1 day before the IPL treatments and resumed application of TC and inactive creams 1 day after IPL treatments. After the second IPL treatment at week 6, patients resumed and continued applications of the creams until the last visit at week 10.

Efficacy was analyzed in the intention-to-treat (ITT) population, which included all enrolled patients (e.g., assigned a patient number), and the per-protocol population, which included patients without protocol deviations. The primary efficacy end point was the evaluation of melasma severity at week 10 using the investigator's global assessment (IGA), which was based on a 5-point scale (0 = clear, 1 = almost clear, 2 = mild, 3 = moderate, 4 = severe). At the week 6 and 10 visits, the investigator and the patients evaluated improvement in melasma

based on a 5-point scale (0 = worse, 1 = no change, 2 = improved, 3 = much improved, 4 = excellent improvement).

Any patient who received at least one dose of study medication was evaluable for adverse events (AEs) and tolerability. These patients were included in the safety population. Tolerability assessments were evaluated at each study visit and included the evaluation of erythema, scaling, dryness, stinging or burning, edema, and telangiectasias, which were based on a 4-point scale (0 = none, 1 = mild, 2 = moderate, 3 = severe). Tolerability assessments associated with IPL were also performed 2 and 6 weeks after the IPL treatment and included the evaluation of erythema, darkening of the melasma lesions, and telangiectasias, which were based on a 4-point scale (0 = none, 1 = mild, 2 = moderate, 3 = severe). AEs were monitored throughout the study, and severity and relatedness to the study treatments were reported.

Descriptive statistics were used to summarize demographic data, tolerability end points, and AEs. The Cochran-Mantel-Haenszel test, after riddit transformation and controlling for investigative site, was used to compare IPL plus TC cream with IPL plus inactive cream at weeks 6 and 10 for IGA and investigator’s and patient’s evaluation of improvement.

**Results**

Fifty-six patients were enrolled in this study, and all were included in the ITT population (N = 56, Table 1). All patients in the ITT population were female (100%), with the majority being white (57%, n = 32) or other or mixed (36%, n = 20) and had Fitzpatrick skin type II (14%, n = 8), III (71%, n = 40) or IV (14%, n = 8). The mean age of the patients was 43.3 ± 9.0, with a mean duration of melasma of 8.9 ± 8.1 years.

Melasma severity was evaluated using a static IGA scale. At baseline, 93% (n = 52) of the patients were

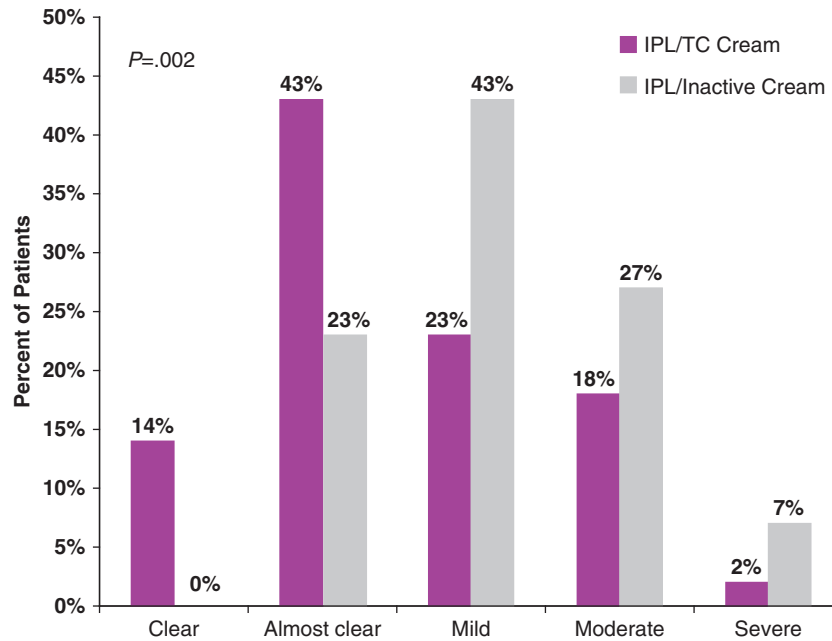
**TABLE 1. Patient Demographics, Intention-to-Treat Population**

Demographic Characteristic	Value
Female, n (%)	56 (100)
Ethnicity, n (%)	
Hispanic	20 (36)
Not Hispanic	36 (64)
Race, n (%)	
White	32 (57)
Asian	2 (4)
American Indian or Alaska Native	1 (2)
Native Hawaiian or other Pacific Islander	1 (2)
Other or mixed	20 (36)
Fitzpatrick skin type, n (%)	
II	8 (14)
III	40 (71)
IV	8 (14)
Age	
mean ± SD	43.3 ± 9.0
Median (range)	42.0 (26.0–69.0)
Duration of melasma, years	
mean ± SD	8.9 ± 8.1
Median (range)	6.5 (0.5–45.0)

SD, standard deviation.

classified as moderate, and 7% (n = 4) were classified as severe in both treatment groups. The distribution of melasma severity in the ITT population was significantly different between the two treatment groups at weeks 6 (p = .007, data not shown) and 10 (p = .002) in favor of TC cream (Figure 1). At week 6, 41% (n = 23) of patients in the TC cream group and 15% (n = 8) in the inactive cream group were clear or almost clear. At week 10, 57% (n = 32) of patients in the TC cream group and 23% (n = 13) in the inactive cream group were clear or almost clear.

Improvement in melasma was greater on the side of the face treated with sequential treatments of TC cream and IPL than on the side of the face treated with sequential treatments of inactive cream and IPL according to the investigator’s evaluation of improvement at weeks 6 and 10 (p < .001 for both time points). The investigator determined that 21% (n = 12) of patients at week 6 and 30% (n = 17) at



**Figure 1.** Melasma severity according to investigator's global assessment at week 10.

week 10 had excellent improvement with IPL plus TC cream. No patient demonstrated excellent improvement with IPL plus inactive cream at either time point.

In the patients' evaluation of improvement, 16% ( $n = 9$ ) rated improvement as excellent at week 6, and 30% ( $n = 17$ ) rated improvement as excellent at week 10 with IPL plus TC cream treatment. Nine percent ( $n = 5$ ) of patients rated improvement as excellent at week 6 and 5% ( $n = 3$ ) at week 10 for IPL plus inactive cream treatment. The distribution of responses for the patients' evaluation of improvement significantly favored IPL plus TC cream over IPL plus inactive cream at both time points ( $p < .001$ ).

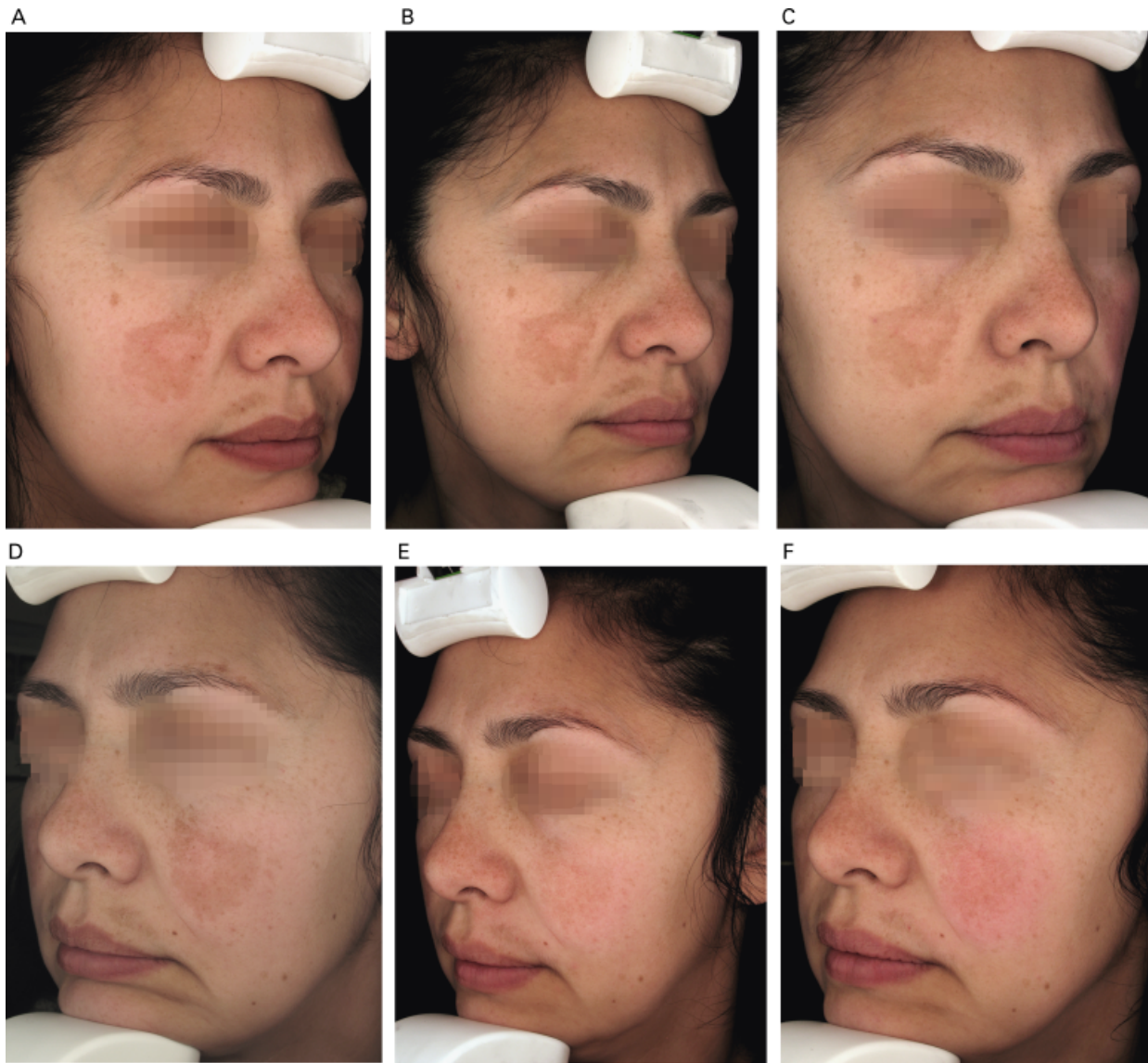Similar statistically significant results were seen in the per-protocol population (data not shown). Representative patient photos which documented the efficacy of the study treatments are shown in Figures 2 through 5.

Treatment with IPL plus TC cream was well tolerated, although cutaneous irritation was greater

with IPL plus TC cream than with IPL plus inactive cream ( $P \leq .025$  for all assessments). The worst severity reported for postbaseline cutaneous irritation is summarized in Table 2. Nine AEs were reported (6 mild (67%), 3 moderate (33%)). Only one event was reported as probably related to the study treatment (small skin erosion, mild in severity), with six events classified as definitely unrelated and two events as unlikely to be related. There was one serious AE (allergic reaction to intravenous pyelography dye) reported in this study. No evidence of erythematous footprinting occurred in any patient from the IPL treatments.

## Discussion

The beneficial effects of the combined components of TC cream (fluocinolone acetonide 0.01%, hydroquinone 4%, and tretinoin 0.05%) have been known for more than 30 years and were first reported by Kligman and Willis.<sup>28,29</sup> Kligman and Willis' formulated cream contained a hydroquinone (5%), tretinoin (0.1%), and a topical corticosteroid (0.1% dexamethasone).<sup>28</sup> They reported that tretinoin changed the skin barrier, which facilitated the

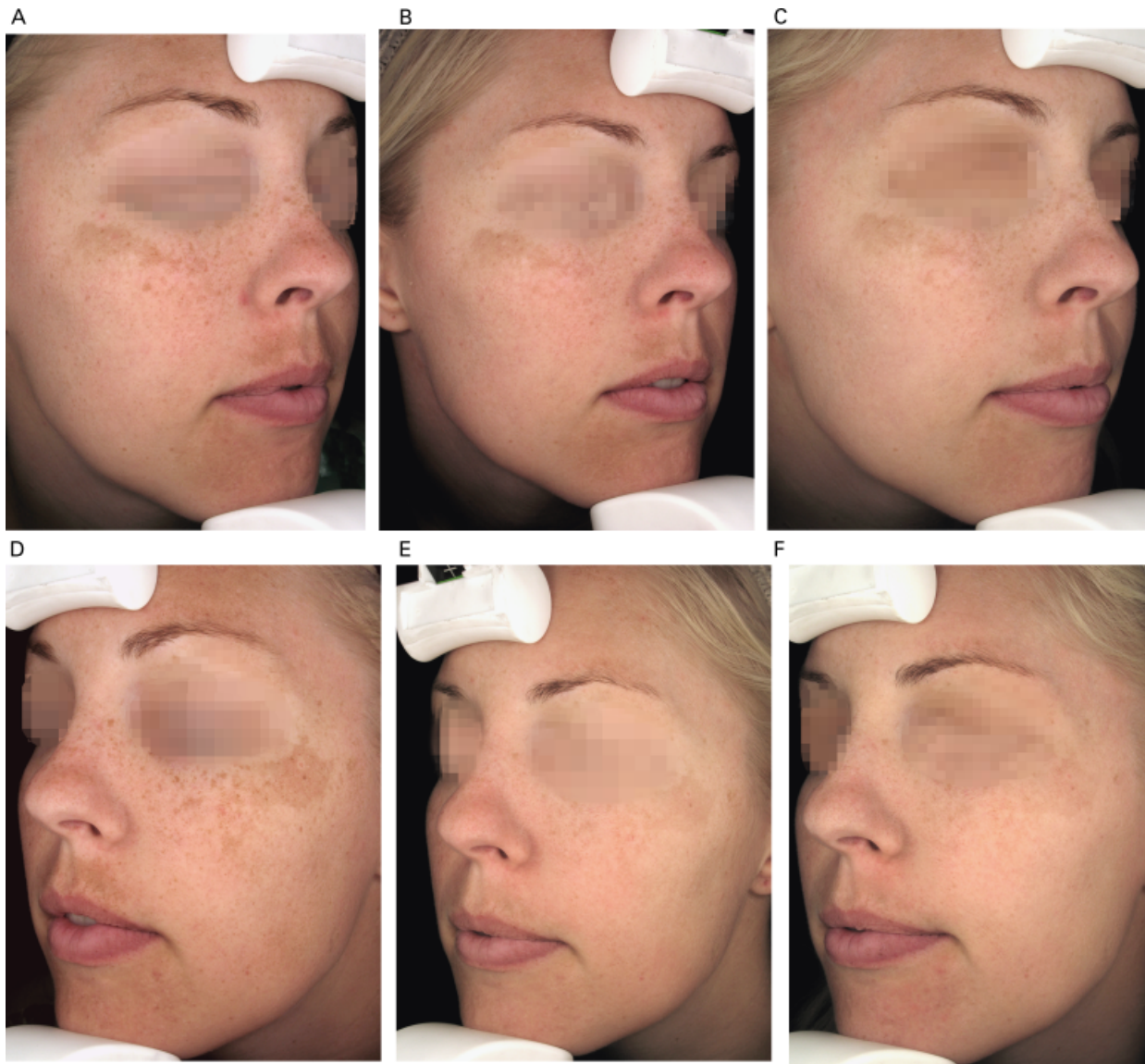

**Figure 2.** Patient 062: (A)–(C) Inactive cream and IPL; baseline, week 6, and week 10. (D)–(F) TC cream and IPL; baseline, week 6, and week 10.

penetration of hydroquinone. They also reported that the corticosteroid component reduced the irritation associated with the retinoid and that the retinoid normalized skin thinning associated with the corticosteroid.<sup>28,30</sup>

Kligman and Willis examined African-American skin and reported that, after 5 to 7 weeks of daily application of their three-component formulation, complete depigmentation of the normal skin in these black male patients was observed. In addition,

depigmentation was not observed when any one of the three components was removed from the formulation. Kligman and Willis hypothesized that the corticosteroid component of their formulation suppressed the biosynthetic and secretory functions of melanocytes, suppressing melanin production. From Kligman and Willis' findings, similar effects of the three components in TC cream may be predicted. The low-potency fluocinolone acetonide in TC cream is believed to exert an antimetabolic effect that can decrease epidermal

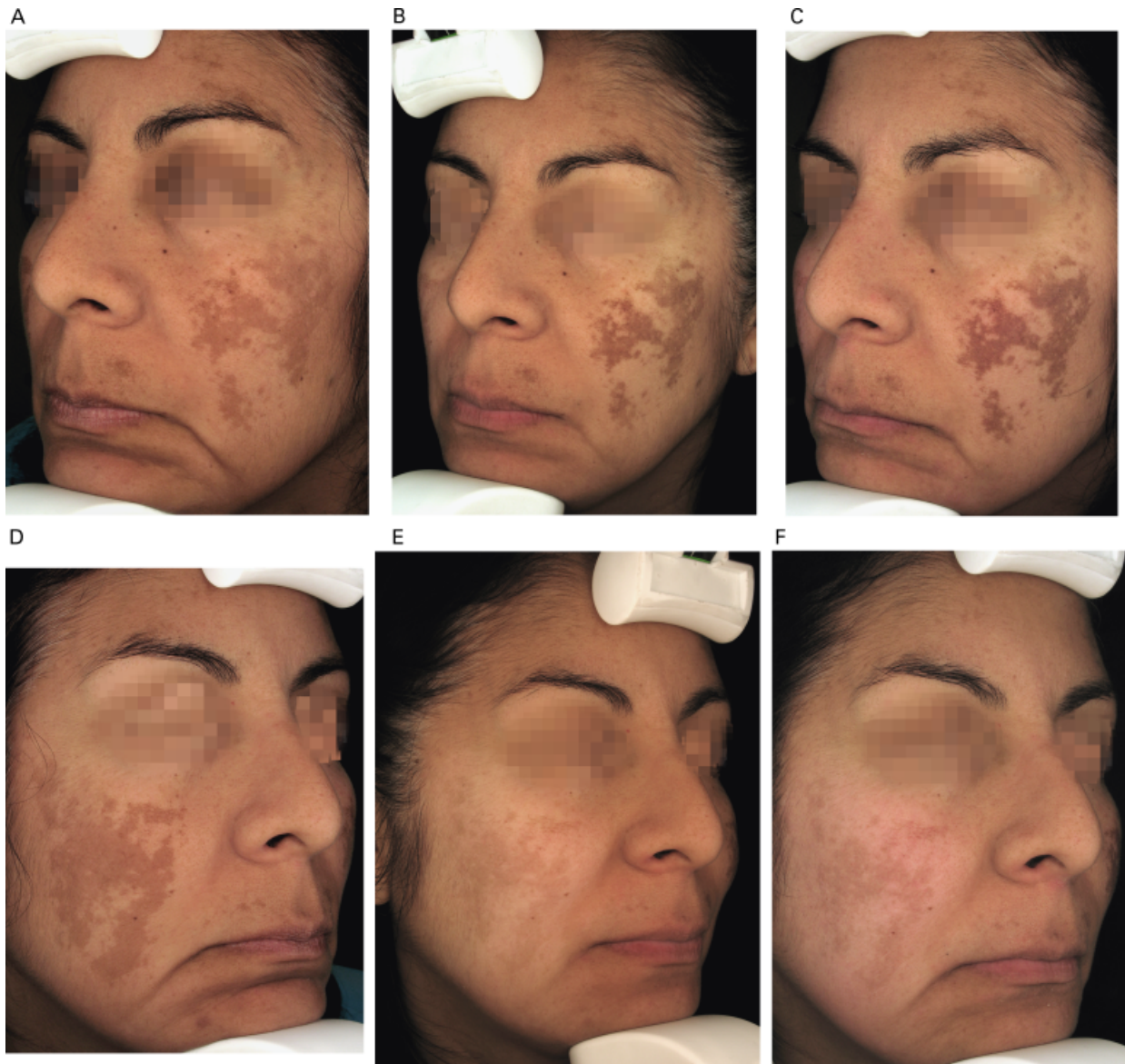

**Figure 3.** Patient 083: (A)–(C) Inactive cream and IPL; baseline, week 6, and week 10. (D)–(F) TC cream and IPL; baseline, week 6, and week 10.

turnover and may have caused mild depigmenting in the treated areas.<sup>29</sup> Furthermore, when combined with tretinoin and hydroquinone, fluocinolone acetonide 0.01% in TC cream may have suppressed the biological functions of melanocytes, which in turn decreased melanin production.<sup>29</sup>

Furthermore, collective results from clinical studies have demonstrated the efficacy of TC cream and its safe profile when used intermittently over 12 months.<sup>19–21</sup> Efficacy with TC cream was reported

as 77% of 641 patients being clear or almost clear of melasma after 8 weeks.<sup>19</sup> Erythema, peeling, stinging, and burning were reported. Two 12-month studies reported clear or almost clear rates of 80% ( $N = 327$  who completed 12 months) and 90% ( $n = 173$  who completed 12 months).<sup>20,21</sup> In controlled clinical trials of TC cream, the most frequently reported events were erythema, desquamation, burning, dryness, and pruritus at the site of application. The majority of these events were mild to moderate in severity.



**Figure 4.** Patient 099: (A)–(C) Inactive cream and IPL; baseline, week 6, and week 10. (D)–(F) TC cream and IPL; baseline, week 6, and week 10.

Therapy that includes the use of TC cream with dermatologic procedures such as chemical peels, microdermabrasion, and laser treatments may optimize the improvements in melasma according to multiple case reports and one small study.<sup>2,12,18,31–33</sup> Corticosteroids are known to have anti-inflammatory properties.<sup>34–36</sup> It is conceivable that the corticosteroid component of TC cream may be partially responsible for the enhanced effects seen when TC cream is used in conjunction with

dermatologic procedures by reducing any procedure-induced inflammation.

Clinical studies have indicated that IPL is an effective and safe treatment for melasma.<sup>25,37–39</sup> One study of 89 Chinese women with melasma who were treated with IPL reported that 77% of patients had at least 50% improvement in melasma.<sup>37</sup> AEs included erythema, edema, desquamating microcrust, and postinflammatory hyperpigmentation.



**Figure 5.** Patient 093: (A)–(C) Inactive cream and IPL; baseline, week 6, and week 10. (D)–(F) TC cream and IPL; baseline, week 6, and week 10.

Another study of 17 Taiwanese women with mixed melasma treated with IPL and hydroquinone reported an average 40% improvement in relative melanin index. AEs including erythema, pain, microcrust formation, and postinflammatory hyperpigmentation were reported.<sup>37</sup> Finally, a recent study in 38 patients of IPL for melasma reported excellent response in 47% of patients and good response in 29%.<sup>27</sup> No complications were reported.

Results from the present study showed that TC cream used sequentially with a series of two IPL treatments was efficacious and safe in the treatment of moderate to severe melasma and that significantly better results were seen with IPL plus TC cream than with IPL plus inactive cream ( $p < .002$ ). The success rate (clear to almost clear) in the ITT population was 57%, with a failure rate of 43% at week 10. Melasma is difficult to treat. There are many possible reasons for treatment

**TABLE 2. Worst Postbaseline Severity of Cutaneous Irritation**

Adverse Event	%					
	Mild		Moderate		Severe	
	TC	Inactive	TC	Inactive	TC	Inactive
Erythema*	41	25	25	5	5	0
Scaling*	29	4	7	0	0	0
Dryness*	41	5	4	0	2	0
Stinging or burning*	27	2	4	0	0	0
Edema**	11	2	5	0	0	0
Telangiectasia**	50	32	11	4	2	0

All patients received intense pulsed light to the entire face, in addition to triple combination (TC) cream on one side and inactive cream on the other side (randomized).  
\**p* < .001, \*\* .025.

failure, such as unprotected sun exposure, hormonal fluctuations, and deep or dermal melasma. The efficacy of IPL and TC cream seen in this study is similar to the efficacy seen in an earlier study in which patients were treated with TC cream and glycolic acid peels.<sup>17</sup> In that study, treatment with TC cream and glycolic acid peels resulted in IGA ratings of clear to almost clear in 65% of the patients by week 12 (*p* < .001). In the present study, one AE was designated as probably related to treatment (mild skin erosion). More experience with this combination treatment approach is needed to determine the frequency of treatment and clinical significance of this finding when using TC cream and IPL together.

Collectively, the results from this study indicate that TC cream used sequentially with a series of two IPL treatments is an efficacious and well-tolerated option for patients with melasma. Cosmetic procedures are often no longer thought of as one-step processes but often include a multistep regimen. Treating with TC cream and IPL enhances results of IPL alone (*p* < .002). Gathering information on the safety and efficacy of various combinations of drug therapies and procedures will aid in tailoring individual regimens to patient need and preference.

**References**

1. Pandya AG, Guevara IL. Disorders of hyperpigmentation. *Dermatol Clin* 2000;18:91-8, ix.

2. Rendon MI. Utilizing combination therapy to optimize melasma outcomes. *J Drugs Dermatol* 2004;3(5 Suppl):S27-34.

3. Grimes PE. Melasma. Etiologic and therapeutic considerations. *Arch Dermatol* 1995;131:1453-7.

4. Prignano F, Ortonne JP, Buggiani G, Lotti T. Therapeutical approaches in melasma. *Dermatol Clin* 2007;25:337-42, viii.

5. Lieberman R, Moy L. Estrogen receptor expression in melasma: results from facial skin of affected patients. *J Drugs Dermatol* 2008;7:463-5.

6. Schmutz JL. [Physiological skin changes during pregnancy]. *Presse Med* 2003;32:1806-8.

7. Tunzi M, Gray GR. Common skin conditions during pregnancy. *Am Fam Physician* 2007;75:211-8.

8. Muzaffar F, Hussain I, Haroon TS. Physiologic skin changes during pregnancy: a study of 140 cases. *Int J Dermatol* 1998;37:429-31.

9. Johnston GA, Sviland L, McLelland J. Melasma of the arms associated with hormone replacement therapy. *Br J Dermatol* 1998;139:932.

10. Moin A, Jabery Z, Fallah N. Prevalence and awareness of melasma during pregnancy. *Int J Dermatol* 2006;45:285-8.

11. Sanchez NP, Pathak MA, Sato S, et al. Melasma: a clinical, light microscopic, ultrastructural, and immunofluorescence study. *J Am Acad Dermatol* 1981;4:698-710.

12. Gupta AK, Gover MD, Nouri K, Taylor S. The treatment of melasma: a review of clinical trials. *J Am Acad Dermatol* 2006;55:1048-65.

13. Lynde CB, Kraft JN, Lynde CW. Topical treatments for melasma and postinflammatory hyperpigmentation. *Skin Ther Lett* 2006;11:1-6.

14. Torok HM. A comprehensive review of the long-term and short-term treatment of melasma with a triple combination cream. *Am J Clin Dermatol* 2006;7:223-30.

15. Grimes P, Kelly AP, Torok H, Willis I. Community-based trial of a triple-combination agent for the treatment of facial melasma. *Cutis* 2006;77:177-84.

16. Bhalla M, Thami GP. Microdermabrasion: reappraisal and brief review of literature. *Dermatol Surg* 2006;32:809–14.
  17. Rendon M, Cardona LM, Bussear EW, et al. Successful treatment of moderate to severe melasma with triple-combination cream and glycolic acid peels: a pilot study. *Cutis* 2008;82:372–8.
  18. Perez-Bernal A, Munoz-Perez MA, Camacho F. Management of facial hyperpigmentation. *Am J Clin Dermatol* 2000;1:261–8.
  19. Taylor SC, Torok H, Jones T, et al. Efficacy and safety of a new triple-combination agent for the treatment of facial melasma. *Cutis* 2003;72:67–72.
  20. Torok H, Taylor S, Baumann L, et al. A large 12-month extension study of an 8-week trial to evaluate the safety and efficacy of triple combination (TC) cream in melasma patients previously treated with TC cream or one of its dyads. *J Drugs Dermatol* 2005;4:592–7.
  21. Torok HM, Jones T, Rich P, et al. Hydroquinone 4%, tretinoin 0.05%, fluocinolone acetonide 0.01%: a safe and efficacious 12-month treatment for melasma. *Cutis* 2005;75:57–62.
  22. Goldberg DJ. Laser removal of pigmented and vascular lesions. *J Cosmet Dermatol* 2006;5:204–9.
  23. Goldman MP, Weiss RA, Weiss MA. Intense pulsed light as a nonablative approach to photoaging. *Dermatol Surg* 2005;31(9 Pt 2):1179–87; discussion 1187.
  24. Moreno Arias GA, Ferrando J. Intense pulsed light for melanocytic lesions. *Dermatol Surg* 2001;27:397–400.
  25. Chan HH, Kono T. The use of lasers and intense pulsed light sources for the treatment of pigmentary lesions. *Skin Ther Lett* 2004;9:5–7.
  26. Radmanesh M, Mostaghimi M, Yousefi I, et al. Leukotrichia developed following application of intense pulsed light for hair removal. *Dermatol Surg* 2002;28:572–4; discussion 574.
  27. Zoccali GPD, Allegra P, Giuliani M. Melasma treated with intense pulsed light. *Aesthetic Plast Surg* 2010;34:486–93.
  28. Kligman AM, Willis I. A new formula for depigmenting human skin. *Arch Dermatol* 1975;111:40–8.
  29. Menter A. Rationale for the use of topical corticosteroids in melasma. *J Drugs Dermatol* 2004;3:169–74.
  30. Wicke C, Halliday B, Allen D, et al. Effects of steroids and retinoids on wound healing. *Arch Surg* 2000;135:1265–70.
  31. Sarkar R, Kaur C, Bhalla M, Kanwar AJ. The combination of glycolic acid peels with a topical regimen in the treatment of melasma in dark-skinned patients: a comparative study. *Dermatol Surg* 2002;28:828–32; discussion 832.
  32. Rendon M, Berneburg M, Arellano I, Picardo M. Treatment of melasma. *J Am Acad Dermatol* 2006;54(5 Suppl 2):S272–81.
  33. Manaloto RM, Alster T. Erbium: YAG laser resurfacing for refractory melasma. *Dermatol Surg* 1999;25:121–3.
  34. Fernandes AM, Valera FC, Anselmo-Lima WT. Mechanism of action of glucocorticoids in nasal polyposis. *Braz J Otorhinolaryngol* 2008;74:279–83.
  35. Liberman AC, Druker J, Refojo D, et al. Glucocorticoids inhibit GATA-3 phosphorylation and activity in T cells. *Faseb J* 2009;23:1558–71.
  36. Zimmermann GR, Avery W, Finelli AL, et al. Selective amplification of glucocorticoid anti-inflammatory activity through synergistic multi-target action of a combination drug. *Arthritis Res Ther* 2009;11:R12.
  37. Li YH, Chen JZ, Wei HC, et al. Efficacy and safety of intense pulsed light in treatment of melasma in Chinese patients. *Dermatol Surg* 2008;34:693–700; discussion 700–691.
  38. Wang CC, Hui CY, Sue YM, et al. Intense pulsed light for the treatment of refractory melasma in Asian persons. *Dermatol Surg* 2004;30:1196–200.
  39. Picardo M, Carrera M. New and experimental treatments of cloasma and other hypermelanoses. *Dermatol Clin* 2007;25:353–62, ix.
- 
- Address correspondence and reprint requests to: Lori A. Johnson, PhD, Galderma Laboratories, L.P., 14501 North Freeway, Fort Worth, TX 76177, or e-mail: lori.johnson@galderma.com



本文献由“学霸图书馆-文献云下载”收集自网络，仅供学习交流使用。

学霸图书馆（www.xuebalib.com）是一个“整合众多图书馆数据库资源，提供一站式文献检索和下载服务”的24小时在线不限IP图书馆。

图书馆致力于便利、促进学习与科研，提供最强文献下载服务。

#### 图书馆导航：

[图书馆首页](#)    [文献云下载](#)    [图书馆入口](#)    [外文数据库大全](#)    [疑难文献辅助工具](#)