

# Low-Fluence Q-Switched Neodymium-Doped Yttrium Aluminum Garnet Laser for Melasma with Pre- or Post-Treatment Triple Combination Cream

SE-YEONG JEONG, MD,\* JAE-BIN SHIN, MD,\* UN-CHEOL YEO, MD, PHD,† WON-SERK KIM, MD, PHD,‡  
AND IL-HWAN KIM, MD, PHD\*

**BACKGROUND** Topical triple combination (TC) treatment is considered the primary approach to melasma. Recently, collimated low-fluence 1,064-nm Q-switched neodymium-doped yttrium aluminum garnet (Nd:YAG) laser treatment has attracted attention as an alternative approach.

**OBJECTIVES** To compare the clinical efficacy and adverse effects of low-fluence Q-switched Nd:YAG laser when performed before and after treatment with topical TC using a split-face crossover design.

**METHODS** Thirteen patients with melasma received topical treatment with TC cream or 1,064-nm Q-switched Nd:YAG laser treatment on opposite sides of the face for 8 weeks, and then treatments were reversed for 8 weeks. Responses were evaluated using the Melasma Area and Severity Index scoring system, spectrophotometry measurements, and a subjective self-assessment method.

**RESULTS** After 16 weeks, better results were seen in subjective assessments when laser treatment was used after 8 weeks of topical TC treatment than before usage of TC. There were no significant adverse effects with the laser treatments.

**CONCLUSIONS** Laser treatment after topical TC cream was found to be safer and more effective than the post-treatment use of topical agents.

*The authors have indicated no significant interest with commercial supporters.*

Melasma is an acquired pigmentary disorder that results in localized hyperpigmentation, commonly found in facial skin and in women.<sup>1,2</sup> Although the pathogenesis of melasma has been studied, its cause and pathological mechanisms are not clearly understood.<sup>2-4</sup> Various methods are used to treat the condition, such as the use of sun block agents and avoidance of exposure to the sun, but these methods are not definitive.<sup>2,5</sup>

Tri-luma cream (Galderma Laboratories LP, Fort Worth, TX), which contains 4% hydroquinone (HQ), 0.05% tretinoin, and 0.01% fluocinolone acetonide, is a fixed, stable, commercially available triple combination (TC) cream.<sup>6,7</sup> Several authors have shown TC cream to be safe and effective.<sup>6-8</sup>

Topical TC treatment is considered the first-line therapy for melasma based on clinical evidence.<sup>6-8</sup> Nevertheless, low response to treatment, a high risk of recurrence, and the possibility of skin irritation have been associated with its use.<sup>2</sup>

Chemical peels or laser treatments offer a secondary option for cases that fail to respond to topical treatment or in severe cases of melasma,<sup>9-13</sup> but laser treatment has reportedly failed to treat melasma in many cases because of inflammation and consequent pigmentation and causes excessive thermal damage at high fluences.<sup>14</sup> Recently, “laser toning” treatment was introduced that uses a collimated low-fluence 1,064-nm Q-switched neodymium-doped yttrium aluminum garnet (Nd:YAG) laser (Spectra VRMIII,

\*Department of Department of Dermatology, College of Medicine, Korea University, Seoul, Korea; †Jongno S&U Dermatologic Clinic, Seoul, Korea; ‡Kangbuk Samsung Hospital, Sungkyunkwan School of Medicine, Sungkyunkwan University, Seoul, Korea

Lutronic Corp., Seoul, Korea).<sup>9,11</sup> This laser treatment minimizes thermal damage by using top-hat beam mode, short pulse width, high peak power, and low fluence. With high efficacy and good clinical results, laser treatment is gaining more attention and interest in the market.<sup>9,11,15</sup>

Although topical and laser treatments are the most frequently used modalities for the treatment of melasma, there are no studies using them in combination or comparing them. The objective of this study was to compare the clinical efficacy and adverse effects of laser treatment when used before and after topical TC.

**Subjects and Methods**

**Study Subjects**

Thirteen patients with melasma participated in this randomized, controlled, split-face study from January 2008 to March 2009. Patients' ages ranged from 28 to 53 (mean 43); 12 patients were female, and one was male. Five had Fitzpatrick skin type III, and eight had type IV (Table 1). All patients were healthy, and none had any dermatologic, endocrinologic, hepatic, or any other disorder except for

melasma. Only patients with symmetrically distributed melasma on the face were enrolled in this study. Patients who had previously undergone more than 6 months of treatment for melasma or were pregnant or lactating were excluded. Patients were instructed not to use any other form of treatment or functional cosmetic during the 16-week study period. All patients provided informed consent and fully understood the purpose of this study.

**Treatment Methods**

The TC cream, Tri-luma, was applied every night to one side of the face (group A) for 8 weeks. If skin irritation symptoms developed, such as erythema, a burning sensation, or desquamation, treatment frequency was reduced, and daily application resumed when symptoms subsided. Group B started with laser treatment and was treated with a collimated, 5- to 7-ns pulse width, 1,064-nm Q-switched Nd:YAG laser weekly for 8 weeks. A single physician performed the laser treatments using a collimation hand piece with a 1,064-nm wavelength, a 7-mm spot size, a fluence of 1.6 to 2.0 J/cm<sup>2</sup>, and two passes per treatment session. After the initial 8-week period, treatments were reversed; that is, previously TC

**TABLE 1. Patient Demographic Data and Melasma Area and Severity Index Score Changes in the Two Study Groups**

Patient Number	Sex/ Age	Group A			Group B		
		Initial Score	After 8 Weeks	After 16 Weeks	Initial Score	After 8 Weeks	After 16 Weeks
1	F/38	0.95	0.65	0.3	0.95	0.3	0.65
2	F/28	0.9	1.2	0.3	0.9	0.3	0.3
3	F/45	8.4	8.4	8.4	8.4	8.4	8.4
4	F/45	3	0.9	0.6	3	0	1.8
5	F/41	0.6	0.3	0	0.6	0	0
6	F/38	5.05	8.55	0.9	3.15	0.3	3.15
7	M/53	12.4	12.4	12.4	12.4	12.4	12.4
8	F/50	3.6	0	0	3.6	0	0
9	F/40	1.8	0.3	0	1.8	0	0.3
10	F/43	3.6	4.5	4	3.6	0.3	0.9
11	F/53	1.8	0.6	0.3	1.8	0.6	0.3
12	F/43	1.2	0	0	1.2	0	0.3
13	F/45	1.2	1.2	0	0.2	0	0.3

cream-treated sides were treated with the laser (group A) for 8 weeks, and TC cream was applied for 8 weeks to previously laser-treated sides (group B) (Figure 1).

TC cream was applied after washing and at least 30 minutes before bedtime. After laser treatment, steroid ointment (Dermatop-oint, prednicarbate 0.1% (Dermatop Ointment, prednicarbate 0.1%, Dermik Laboratories, Bridgewater, NJ)) was applied to reduce inflammation. A sunscreen with sun protection factor of 50 and UVA and UVB protection and moisturizer were provided for daily use. Protective clothing and the avoidance of direct facial exposure to the sun was recommended.

### Efficacy Assessments

Responses to treatments and adverse effects were evaluated weekly throughout the 16-week treatment period. A single physician performed all efficacy assessments. Clinical images were taken using a Sony digital camera (DSC-F828, Sony, Tokyo, Japan). The Melasma Area and Severity Index (MASI) scoring system was used to score facial sides. In addition, a spectrophotometer (CM-2006D, Minolta, Tokyo, Japan) was used to measure skin color and brightness using  $L^*$ ,  $a^*$ ,  $b^*$ , and  $\Delta E^*ab$  values. Measurements were obtained in triplicate, and values were averaged. Patients were also requested to

self-evaluate treatment progress based on a clinical image evaluation during an interview. Responses were graded as worse, no change, improved (<50%), much improved (>50%), and cleared state (complete disappearance of melasma).

A single physician conducted long-term follow-up (11 months after treatment cessation) over the telephone using patients' subjective grades.

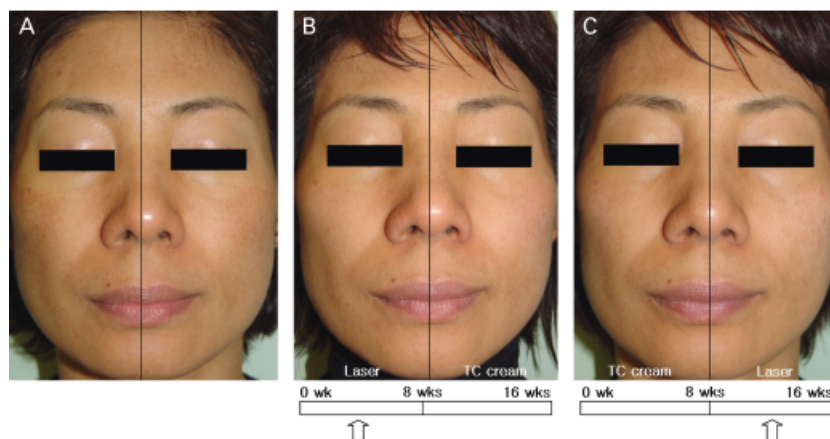
### Statistical Analysis

Statistical analyses were performed using SYSTAT 11.0 software (SYSTAT, Richmond, CA). MASI scores and spectrophotometer measurements ( $L^*$ ,  $a^*$ ,  $b^*$ , and  $\Delta E^*ab$  values) were analyzed using the nonparametric Wilcoxon signed-rank test for paired data. The subjective self-assessment data were analyzed using correspondence analysis.  $P < .05$  was accepted as significant.

## Results

### MASI Score

MASI scores in group A (TC cream followed by laser treatment) reduced from  $3.42 \pm 3.46$  to  $3.0 \pm 4.14$  after 8 weeks of TC treatment ( $p > .05$ ) and then to  $2.09 \pm 3.92$  after an additional 8 weeks of laser treatment ( $p < .05$ ) (Tables 1 and 2). Overall



**Figure 1.** Clinical photograph showing the treatment methods. (A) Split faces were assigned randomly. (B) Laser and triple combination cream treatment were administered to opposite sides of the face for 8 weeks. (C) Treatment sides were subsequently reversed for an additional 8 weeks.

**TABLE 2. Summary of Changes in Melasma Area and Severity Index Scores and L\* and ΔE\*ab Values in the Two Study Groups**

	Group A			Group B		
	Initial	After 8 Weeks	After 16 Weeks	Initial	After 8 Weeks	After 16 Weeks
MASI score	3.42 ± 3.46	3.00 ± 4.14	2.09 ± 3.92*	3.20 ± 3.49	1.74 ± 3.93*	2.22 ± 3.82*
L* value	58.57 ± 4.03	58.74 ± 4.45	60.78 ± 4.44*	58.63 ± 4.63	59.71 ± 4.80	59.10 ± 5.37
ΔE*ab value	5.62 ± 3.01	5.51 ± 2.92	3.86 ± 2.37	4.96 ± 4.00	4.69 ± 2.45	5.28 ± 2.70

\**p* < .05, The statistical significance after 16 weeks is evaluated between the result of 8 and 16 weeks.

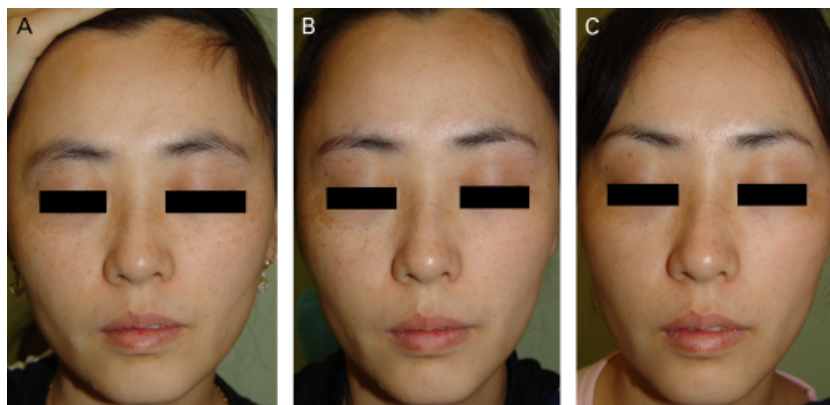
improvement for group A during the 16-week treatment period was statistically significant (*p* < .05). In group B, MASI scores dramatically reduced from an initial score of 3.20 ± 3.49 to 1.74 ± 3.93 after 8 weeks of laser treatment (*p* < .05) and increased to 2.22 ± 3.82 after an additional 8 weeks of TC treatment (*p* < .05) (Tables 1 and 2). Although the MASI score increased during the additional 8 weeks, the overall improvement was statistically significant (*p* < .05).

Comparison of the two modalities during each period showed that laser treatment was more effective than TC treatment (*p* < .05). During the additional 8 weeks, most of the patients who developed poor responses after TC treatment improved after laser treatment (Figure 2). MASI scores increased in seven patients in group B after TC treatment (Figure 3).

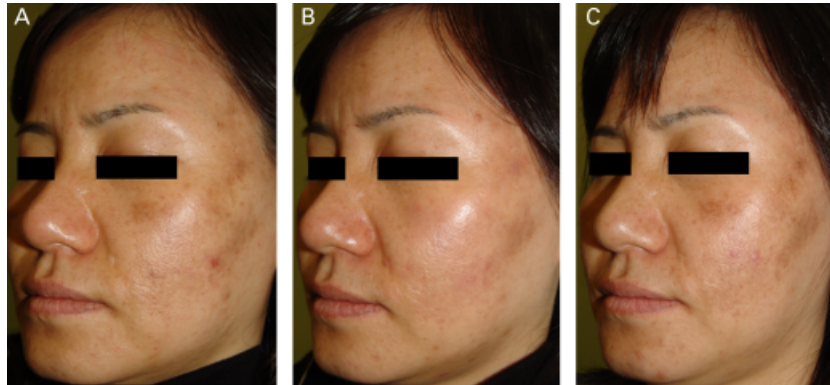
Although the difference in overall improvement between the two groups was statistically nonsignificant (*p* > .05), this might have been due to a small sample size.

**Spectrophotometer Measurements**

L\* represents brightness; a higher L\* reflects a brighter skin tone. L\* in group A remained almost unchanged after 8 weeks of TC treatment (58.57 ± 4.03 to 58.74 ± 4.45) (*p* > .05), but after 8 weeks of laser treatment, it increased significantly to 60.78 ± 4.44 (*p* < .05). Overall improvement in group A during the 16-week treatment period was statistically significant (*p* < .05). Conversely, L\* in group B increased from 58.63 ± 4.63 to 59.71 ± 4.80 after 8 weeks of laser treatment (*p* > .05), although after an additional 8 weeks of TC



**Figure 2.** In the photograph, the right side was aggravated after 8 weeks of triple combination (TC) cream treatment, whereas the left side was almost cleared by laser treatment. After 16 weeks, the aggravated right side had been cleared by laser treatment, and no recurrence had occurred on the left side after TC cream treatment. (A) Before treatment, (B) after 8 weeks, and (C) after 16 weeks.



**Figure 3.** This melasma lesion was mostly cleared by 8 weeks of laser treatment, but the lesion was aggravated after an additional 8 weeks on triple combination (TC) cream. (A) Before treatment, (B) after 8 weeks of laser treatment, and (C) after an additional 8 weeks of TC cream treatment.

treatment, it fell to  $59.10 \pm 5.37$  ( $p > .05$ ). In contrast to group A, overall improvement was statistically nonsignificant ( $p > .05$ ).

Comparison of the two modalities during each period showed that the laser treatment was more effective than TC cream in the additional 8 weeks of treatment ( $p < .05$ ). Although the difference in overall improvement between the two groups was statistically nonsignificant ( $p > .05$ ), that might have been due to small sample size.

$\Delta E^*_{ab}$  values quantify overall color differences; lower  $\Delta E^*_{ab}$  values means there is less of a difference between melasma lesions and normal facial skin. The mean  $\Delta E^*_{ab}$  value for group A fell marginally from  $5.62 \pm 3.01$  to  $5.51 \pm 2.92$  after 8 weeks of TC treatment ( $p > .05$ ) and fell significantly to  $3.86 \pm 2.37$  after an additional 8 weeks of laser treatment ( $p > .05$ ). In group B, the mean  $\Delta E^*_{ab}$  reduced significantly from  $4.96 \pm 4.00$  to  $4.69 \pm 2.45$  after 8 weeks of laser treatments ( $p > .05$ ) and increased to  $5.28 \pm 2.70$  after an additional 8 weeks of TC cream treatment ( $p > .05$ ) (Table 2). The statistical significances were the same as the results from  $L^*$ .

### **Subjective Assessment**

After the initial 8 weeks of TC treatment, 3 patients in group A showed aggravation (23%, patients 2, 6,

10), two showed no response (15%, patients 3, 7), four showed improvement (32%, patients 1, 5, 9, 11), two showed much improvement (15%, patients 4, 13), and two achieved a cleared state (15%, patients 8, 12). Similarly, after 8 weeks of laser treatment (0%), none of the patients in group B showed aggravation (0%), two had no response (15%, patients 3, 7), one showed improvement (8%, patient 1), three showed much improvement (32%, patients 2, 6, 10, 11), and six achieved a cleared state (45%, patients 4, 5, 8, 9, 12, 13).

After an additional 8 weeks of treatment, no patients in group A showed aggravation (0%), two had no response (15%, patients 3, 7), three showed improvement (23%, patients 1, 4, 10), three showed much improvement (23%, patients 2, 6, 11), and five achieved a cleared state (39%, patients 5, 8, 9, 12, 13). Similarly, seven patients in group B showed aggravation (55%, patients 1, 4, 6, 9, 10, 12, 13), three had no response (23%, patients 2, 3, 7), one showed improvement (7%, patients 11), none showed much improvement (0%), and two achieved a cleared state (15%, patients 5, 8) (Table 3).

The interpretation of correspondence analysis is based on the interpoint distances. The proximity between two points means that they are similar. Results from the correspondence analysis for the initial 8 weeks showed that A8 (group A) in the left

**TABLE 3. Results of Patients' Subjective Self-Assessments**

	n (%)			
	Group A		Group B	
	After 8 Weeks	After 16 Weeks	After 8 Weeks	After 16 Weeks
Worse	3 (23)	0 (0)	0 (0)	7 (55)
No change	2 (15)	2 (15)	2 (15)	3 (23)
Improved	4 (32)	3 (23)	1 (7)	1 (7)
Much improved	2 (15)	3 (23)	3 (23)	0 (0)
Completely improved	2 (15)	5 (39)	6 (45)	2 (15)

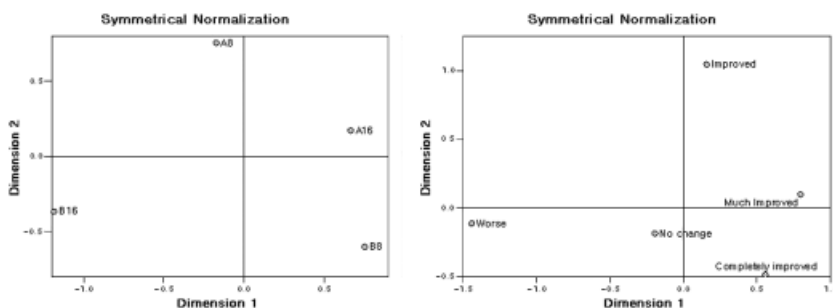
figure was close to “improved” in the right figure and B8 (group B) was close to “completely improved” in the right figure. In the same method, after 16 weeks, group A was close to “much improved” and group B was close to “worse” (Figure 4). Collectively, laser treatment with a pretreatment of TC cream was significantly more effective than post-treatment use of TC cream. In addition, aggravation was only observed for TC treatment.

**Recurrence and Adverse Effects**

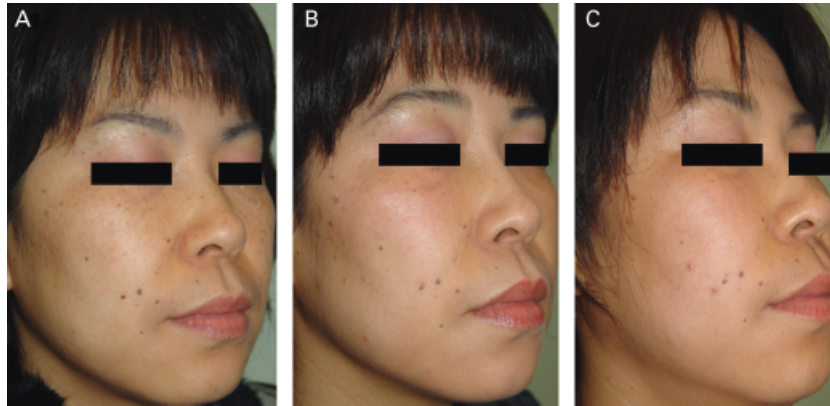
After 8 weeks of initial treatment, the conditions of three patients (23%) worsened in group A; no patient worsened in group B after the initial 8 weeks of laser treatment (Figure 2). After an additional 8 weeks of treatment, all patients in group A, except two who showed no response, showed improvement (Figure 5). In group B, only two of six patients cleared by laser treatment were maintained without

recurrence, the other four showed partial recurrence (Figure 3). Of the five partially improved patients in group B after laser treatment, only one showed more improvement after TC treatment, and one patient was maintained by TC without recurrence. Three patients worsened on TC. In general, laser treatment maintained the conditions of the majority of patients in group A, whereas it did not maintain the conditions of the majority of patients in group B.

In terms of TC application, the most severe adverse effect was aggravation of the melasma, which developed in three patients. Four patients experienced irritation after TC application, which was controlled by extending intervals between applications for a period of time. No other complications occurred. The adverse effects that occurred after laser treatment were mild pain and erythema. Punctate leucoderma and postinflammatory hypopigmentation did not occur in any patient.



**Figure 4.** Correspondence analysis of subjective assessments. A8, Subjective assessment after initial 8 weeks in group A. A16, Subjective assessment after additional 8 weeks in group A. B8, Subjective assessment after initial 8 weeks in group B. B16, Subjective assessment after additional 8 weeks in group B.



**Figure 5.** This patient showed partial improvement after 8 weeks on triple combination (TC) cream, but after an additional 8 weeks of laser treatment, the lesion totally cleared. (A) Before treatment, (B) after 8 weeks of TC treatment, and (C) after an additional 8 weeks of laser treatment.

Results from long-term follow-up 11 months after treatment cessation revealed complete remission in two patients (patients 5, 8, cure at cessation of treatments) and no overall improvement in two (patients 3, 7). The other nine patients showed mildly worse conditions than at treatment cessation, but no patient showed deterioration from his or her initial condition.

## Discussion

Many therapeutic approaches have been used to treat melasma, but protection of the skin from ultraviolet radiation remains one of the most important managements.<sup>2,5</sup> These treatments include hypopigmenting agents, chemical peels, dermabrasion, and laser treatments.<sup>2,6-15</sup> The most frequently used topical bleaching agent is HQ. Several studies have reported good efficacy for topical HQ therapy. HQ is commercially available in concentrations from 2% to 5%,<sup>6</sup> but HQ monotherapy has also been reported to be relatively ineffective and to have a high recurrence rate.<sup>2,16</sup> In 1975, Kligman and Willis published an impressive study on the use of a topical combination therapy (5% HQ, 0.1% tretinoin, and 0.1% dexamethasone) for the depigmentation of skin.<sup>17</sup> Several articles subsequently proposed various other combination therapies for melasma<sup>6-8,18,19</sup> that were usually based on topical formulations

containing HQ and tretinoin. Several studies have reported that the efficacies of these topical therapies vary from approximately 40% to 80% and that they had many shortcomings, such as a lack of objective spectrophotometry data or lack of long-term follow-up.<sup>6-8</sup> A stable TC therapy (Tri-luma cream) consisting of 4% HQ, 0.05% tretinoin, and 0.01% fluocinolone acetonide was recently developed.<sup>6,7</sup> The studies using this new TC cream have showed that 8 weeks of treatment is effective and that there are no significant adverse effects.<sup>20,21</sup> The 8-week duration of the TC treatment in our study was based on these findings. In long-term use, this cream achieved improvement in 76% of patients with melasma after 6 months and of 97% after 12 months;<sup>7</sup> mild adverse effects were reported in 57% of cases.<sup>6</sup> Few articles have addressed recurrence and adverse effects after TC therapy as compared with other topical therapies and chemical peeling, but no studies using a combination method or comparison of both modalities has been reported.<sup>8,18</sup>

Despite the primary use of TC cream in practice, its efficacy is unsatisfactory because of low long-term adherence and the aggravated conditions reported in some cases. Furthermore, the methodological limitations of topical treatments are well known. From 2005, several attempts to mechanically remove melanin or destroy melanosomes have been made

using lasers in melasma. Lasers are pigment selective at 510-, 694-, 755-, and 1,064-nm wavelengths,<sup>10,22,23</sup> although the 1,064-nm laser is considered the most suitable in terms of dermal pigment treatment.<sup>9,11,23</sup> However, the fluence used in these earlier studies was too high, and thus they caused predictable complications. In 2005, a new laser that provides fractional photothermolysis was used for melasma treatment, but no randomized controlled trial has been reported on this treatment method.<sup>24</sup> "Laser toning," which uses a collimated low-fluence 1,064-nm Q-switched Nd:YAG laser, has been recently introduced for the treatment of melasma. This laser treatment minimizes thermal damage by using top-hat beam mode, short pulse width, high peak power, and low fluence.<sup>9-11</sup> However, although laser toning is commonly used in Asian practice, the exact mechanism involved is not well understood.

In this study, we compared two different combination methods: TC treatment followed by laser treatment and laser treatment followed by TC treatment. A follow-up was conducted 11 months after treatment discontinuation. The most notable finding of this study was that group A (TC treatment followed by laser treatment) showed a better outcome after 16 weeks of treatment. Compared with group B, the MASI and spectrophotometer results in group A improved more in six patients, stayed the same in four patients, and were more aggravated in one patient. This result was supported only by correspondence analysis of the subjective assessment. The MASI score results and spectrophotometer measurements were statistically nonsignificant, although this nonsignificance might be due to a small sample size. The required sample size to satisfy statistical significance is at least 200 subjects and was a limitation of this study. Another notable finding was that laser treatment was found to be more effective than TC cream. The pre- to post-TC treatment MASI score was 0.42 in the initial 8 weeks, whereas it was 1.46 after laser treatment. Furthermore, 45% of the patients in group B showed complete resolution after initial laser treatment, which was three times more

than the 15% (2 patients) after initial TC treatment. This result was supported by the MASI score in the initial and additional 8 weeks of treatment and spectrophotometer measurements of the additional 8 weeks ( $p < .05$ ). The last finding is that no aggravation was observed after initial laser treatment, whereas three cases (23%) showed aggravation after the initial TC treatment. Furthermore, all three aggravated patients improved on subsequent laser treatment, which also improved the conditions of patients that showed partial response to TC treatment. On the other hand, the majority of cases in group B showed lesion recurrence or worsening after TC administration, whereas three patients in group A failed to respond to TC improvement after laser treatment.

Long-term follow-up results 11 months after treatment cessation revealed a cleared state in two patients and mild aggravation in nine patients. Patients said that recurrence occurred within 3 months after treatments. The two cleared patients had malar type melasma and Fitzpatrick skin type III, which is a bright skin type in Asian people. There was little irritation after TC treatment and little erythema or edema after laser treatment.

It has been reported that laser treatments cause adverse effects, such as punctuate leucoderma, a serious cosmetic problem,<sup>15</sup> but we found that we can prevent this problem by using a low-fluence laser. In the present study, long-term follow-up showed no significant adverse effects. Variable clinical response and recurrence are probably due to factors such as skin sensitivity, telangiectasia, inflammation, and erythema after laser treatment.<sup>9</sup>

Melasma is classified as epidermal, dermal, or mixed.<sup>4,24,25</sup> Various methods, such as Wood's lamp examination, skin stretch measurements, and biopsy, have been used to attempt to differentiate these types, but they are difficult to differentiate clinically.<sup>26</sup> Epidermal-type melasma usually responds well to topical treatment, whereas the dermal and mixed types respond poorly and have high

recurrence rates,<sup>27,28</sup> and thus, treatment methods should be tailored to the melasma type. However, the majority of patients with melasma are of the mixed type, and therefore combined modalities are recommended. In the present study, it was found that TC cream monotherapy is limited and that the combination method is necessary for treatment of melasma. Our findings also showed that maintenance therapy is required to prevent recurrence.

In conclusion, the strongest feature of the present study is that it is the first to study combination treatment methods and comparison of TC cream treatment and collimated low-fluence 1,064-nm Q-switched Nd:YAG laser treatment using objective data and long-term follow-up findings. Laser treatment using a collimated low-fluence Q-switched Nd:YAG laser is safe and effective. The combination method of laser treatment after 8 weeks of TC promises to be one of the most effective methods for the treatment of melasma. Furthermore, our findings show that laser treatment should be considered in melasma cases resistant to TC or that fail to respond to TC.

## References

- Pandya AG, Guevara IL. Disorders of hyperpigmentation. *Dermatol Clin* 2000;18:91-8.
- Gupta AK, Gover MD, Nouri K, et al. The treatment of melasma: a review of clinical trials. *J Am Acad Dermatol* 2006;55:1048-65.
- Ando H, Kondoh H, Ichihashi M, et al. Approaches to identify inhibitors of melanin biosynthesis via the quality control of tyrosinase. *J Invest Dermatol* 2007;127:751-61.
- Kang WH, Yoon KH, Lee ES, et al. Melasma: histopathological characteristics in 56 Korean patients. *Br J Dermatol* 2002;146:228-37.
- Vazquez M, Sanchez JL. The efficacy of a broad-spectrum sunscreen in the treatment of melasma. *Cutis* 1983;32:92-6.
- Torok HM. A comprehensive review of the long-term and short-term treatment of melasma with a triple combination cream. *Am J Clin Dermatol* 2006;7:223-30.
- Torok HM, Jones T, Rich P, et al. Hydroquinone 4%, tretinoin 0.05%, fluocinolone acetonide 0.01%: a safe and efficacious 12-month treatment for melasma. *Cutis* 2005;75:57-62.
- Cestari TF, Hassun K, Sittart A. A comparison of triple combination cream and hydroquinone 4% cream for the treatment of moderate to severe facial melasma. *J Cosmet Dermatol* 2007;6:36-9.
- Jeong SY, Chang SE, Park HN, et al. New melasma treatment by collimated low fluence Q-switched Nd:YAG Laser. *Korean J Dermatol* 2008;46:1163-70.
- Tse Y, Levine VJ, McClain SA, et al. The removal of cutaneous pigmented lesions with the Q-switched ruby laser and the Q-switched neodymium: yttrium-aluminum-garnet laser. *J Dermatol Surg Oncol* 1994;20:795-800.
- Polnikorn N. Treatment of refractory dermal melasma with the Medlite C6 Q-switched Nd:YAG laser: two case reports. *J Cosmet Laser Ther* 2008;10:167-73.
- Hurley ME, Guevara IL, Gonzales RM, et al. Efficacy of glycolic acid peels in the treatment of melasma. *Arch Dermatol* 2002;138:1578-82.
- Erbil H, Sezer E, Tastan B, et al. Efficacy and safety of serial glycolic acid peels and a topical regimen in the treatment of recalcitrant melasma. *J Dermatol* 2007;34:25-30.
- Taylor CR, Anderson RR. Ineffective treatment of refractory melasma and postinflammatory hyperpigmentation by Q-switched ruby laser. *J Dermatol Surg Oncol* 1994;20:592-7.
- Kim MJ, Kim JS, Cho SB. Punctate leucoderma after melasma treatment using 1,064-nm Q-switched Nd:YAG laser with low pulse energy. *J Eur Acad Dermatol Venereol* 2009;23:960-2.
- Haddad AL, Matos LF, Brunstein F, et al. A clinical, prospective, randomized, double-blind trial comparing skin whitening complex with hydroquinone vs placebo in the treatment of melasma. *Int J Dermatol* 2003;42:153-6.
- Kligman AM, Willis I. A new formula for depigmenting human skin. *Arch Dermatol* 1975;111:40-8.
- Astaneh R, Farboud E, Nazemi MJ. 4% hydroquinone versus 4% hydroquinone, 0.05% dexamethasone and 0.05% tretinoin in the treatment of melasma: a comparative study. *Int J Dermatol* 2005;44:599-601.
- Gano SE, Garcia RL. Topical tretinoin, hydroquinone, and beta-methasone valerate in the therapy of melasma. *Cutis* 1979;23:239-41.
- Taylor SC, Torok H, Jones T, et al. Efficacy and safety of a new triple-combination agent for the treatment of facial melasma. *Cutis* 2003;72:67-72.
- Chan R, Park KC, Lee MH, et al. A randomized controlled trial of the efficacy and safety of a fixed triple combination (fluocinolone acetonide 0.01%, hydroquinone 4%, tretinoin 0.05%) compared with hydroquinone 4% cream in Asian patients with moderate to severe melasma. *Br J Dermatol* 2008;159:697-703.
- Grekin RC, Shelton RM, Geisse JK, et al. 510-nm pigmented lesion dye laser. Its characteristics and clinical uses. *J Dermatol Surg Oncol* 1993;19:380-7.
- Anderson RR, Parrish JA. Selective photothermolysis: precise microsurgery by selective absorption of pulsed radiation. *Science* 1983;220:524-7.

24. Rokhsar CK, Fitzpatrick RE. The treatment of melasma with fractional photothermolysis: a pilot study. *Dermatol Surg* 2005;31:1645–50.
25. Katsambas A, Antoniou C. Melasma: classification and treatment. *J Eur Acad Dermatol Venereol* 1995;4:217–75.
26. Gilchrist BA, Fitzpatrick TB, Anderson RR, et al. Localization of melanin pigmentation in the skin with Wood's lamp. *Br J Dermatol* 1977;96:245–8.
27. Negishi K, Kushikata N, Tezuka Y, et al. Study of the incidence and nature of “very subtle epidermal melasma” in relation to intense pulsed light treatment. *Dermatol Surg* 2004;30:881–6.
28. Grimes PE, Yamada N, Bhawan J. Light microscopic, immunohistochemical, and ultrastructural alterations in patients with melasma. *Am J Dermatopathol* 2005;27:96–101.

---

Address correspondence and reprint requests to: Il-Hwan Kim, MD, PhD, Department of Dermatology, Korea University Ansan Hospital, No. 516, Gojan-1-dong, Danwon-ku, Ansan, Gyeonggi-do, 425-707, Korea or e-mail: kumcihk@korea.ac.kr