

Letters

RESEARCH LETTER

Copper Bromide Laser vs Triple-Combination Cream for the Treatment of Melasma: A Randomized Clinical Trial

Recent studies have suggested the potential effectiveness of targeting the vascular component of melasma.¹⁻⁴ The copper bromide laser (Dual Yellow; Narseld) is a laser with a concomitant-output dual-wavelength light source comprising 90% yellow light at 578 nm, which targets vascular lesions, and 10% green light at 511 nm, which targets pigmentary lesions. There are 2 conflicting reports on the potential value of this laser for treating melasma.^{5,6} The objective of this study was to compare the effectiveness of the copper bromide laser vs the Kligman formula combination cream (a combination of hydroquinone, 5%, dexamethasone acetate, 0.1%, and retinoic acid, 0.1%) in the treatment of melasma.

Methods | We conducted a monocentric, prospective, clinical, randomized, split-face study with blinded evaluation in the Department of Dermatology at the University Hospital of Nice between February 2012 and June 2013. This study was approved by the University Hospital of Nice ethical committee, and written informed consent was obtained from all patients. The full study protocol can be found in the trial protocol in the Supplement.

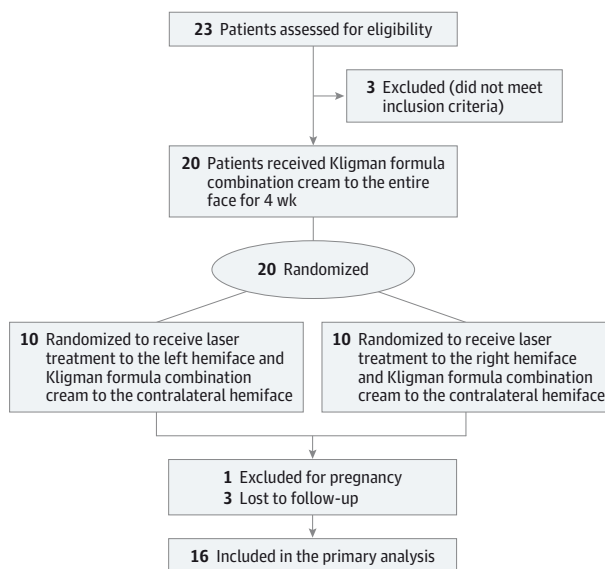
All patients applied the topical cream to their entire face once a day for 4 weeks. A hemiface was then randomly assigned to be treated with the copper bromide laser, while the other side of the face continued to receive daily application of the topical cream for 3 additional months. Four sessions of copper bromide laser were given at weeks 4, 6, 9, and 12. The yellow and green wavelengths were simultaneously produced at a ratio of 9 to 1. The settings applied during the first laser session were: fluence, 12 J/cm²; 0.6-mm contact tip; and 1 pass. Fluencies were progressively increased, as previously reported.⁵ A 1-mm spot size was then used, and 4 passes were performed in each session. The emission time was 50 to 60 milliseconds and the off time was 70 milliseconds, with 7.7 to 8.3 pulses per second. The end point was erythema and a slight graying of the lesions. A colorless ultrasonic gel was applied directly to the skin before laser treatment. Evaluation was conducted using standardized photographs (VISIA-CR; Canfield Scientific) by two of us (H.M. and F.B.) who were masked to the treatment applied on each side of the face. The treatments' effectiveness was assessed using the Melasma Area and Severity Index (MASI) score for each hemiface. Follow-up visits were conducted at 3 and 6 months. The main evaluation criterion was the patient's MASI score 6 months after the end of treatment. Laser confocal microscopy (VivaScope; MAVIG) was

used to evaluate the evolution of the lesions that were treated between the baseline visit and 6 months after the end of the treatment. Effectiveness and tolerance (according to the patient) were assessed at the end of the study using visual analog scales graded from 0 to 10.

Results | Twenty patients with melasma were included. One was excluded for pregnancy and 3 were unavailable for follow-up (Figure). The patients (17 women and 3 men) had a mean (SD) age of 38.4 (6.2) years (range, 30-53 years) and had had melasma for a mean (SD) of 5.6 (3.4) years (range, 0.5-10.9 years). Three patients had skin type II; 10, type III; and 7, type IV. To treat melasma previously, 16 patients had used a cosmetic bleaching agent; 14, Kligman formula combination cream; and 4, laser. Seven patients had melasma on the forehead; 12 on the cheeks; and 1 on the upper lip. Before treatment, the hemifaces randomized to be treated with laser had a mean (SD) MASI score of 7.91 (5.17); those randomized to continue treatment with Kligman formula combination cream had a mean (SD) score of 7.52 (4.14).

At the end of treatment, the topical cream resulted in a greater decrease in the MASI score compared with the laser treatment ($P = .006$). The MASI score at 6 months was comparable with the score at the beginning of the study in both groups; no

Figure. CONSORT Flow Diagram of Study Selection



The flow diagram illustrates the process of screening and selecting the patients for inclusion and exclusion and shows the patients who were unavailable for follow-up during the study. Additional details of the treatment regimens are in the Methods section. Kligman formula combination cream consists of hydroquinone, 5%, dexamethasone acetate, 0.1%, and retinoic acid, 0.1%. Copper bromide laser (Dual Yellow; Narseld) was used for the laser treatments.

Table. Comparison of the Change in MASI Scores for Each Treatment Group^a

Treatment ^b	Baseline (n = 17)	Treatment Conclusion (n = 17)	Follow-up (n = 16)	Change	
				Conclusion – Baseline (n = 17)	Follow-up – Baseline (n = 16)
Kligman formula combination cream	7.29 (4.11)	6.58 (3.30)	7.50 (4.39)	-0.71 (2.05)	-0.02 (1.06)
Kligman formula combination cream followed by laser treatment	7.66 (5.11)	7.81 (4.58)	7.69 (5.16)	0.15 (1.73)	-0.23 (0.76)
P value	NA	NA	NA	.006	.33

Abbreviations: MASI, Melasma Area and Severity Index; NA, not applicable.

^a Data are given as mean (SD) scores. Treatment conclusion indicates values recorded at the end of treatment; follow-up, 6 months after treatment completion.

^b Details of treatment regimens are in the Methods section.

significant difference was observed between the 2 groups (Table). No difference could be found when results were analyzed according to the localization and duration of the melasma ($P > .99$ and $P = .87$, respectively). An increased vascularization was noted on the melasma lesions at baseline compared with perilesional skin using VISIA-CR RBX Red subsurface analysis and laser confocal microscopy. However, no decrease in vascularization was observed on the laser-treated side between the baseline and posttreatment visits. At the final visit, no changes in vascularization were noted between the 2 sides. No scarring or postinflammatory hyperpigmentation was noted.

Discussion | Our results show that Kligman formula combination cream is more effective than the copper bromide laser for treating melasma. At the 6-month follow-up, no difference was observed between the 2 approaches and, in both cases, the MASI scores were similar to those observed before treatment. Neither procedure prevented relapse despite the use of sunscreen in all the patients. The lack of changes in vascularization observed via both RBX Red subsurface analysis and laser confocal microscopy between the topical cream- and laser-treated groups suggests that the copper bromide laser did not effectively target the vascular component of melasma. These results show that Kligman formula combination cream remains the most effective treatment for melasma and show the crucial need for prospective randomized studies with long-term follow-up, compared with Kligman formula combination cream, to confirm the effectiveness of any new approach in treating melasma.

Houda Hammami Ghorbel, MD

Fériel Boukari, MD

Eric Fontas, MD, PhD

Henri Montaudié, MD

Philippe Bahadoran, MD, PhD

Jean-Philippe Lacour, MD

Thierry Passeron, MD, PhD

Author Affiliations: Department of Dermatology, University Hospital of Nice, Nice, France (Hammami Ghorbel, Boukari, Montaudié, Bahadoran, Lacour,

Passeron); Délégation à la Recherche Clinique et à l'Innovation, University Hospital of Nice, Nice, France (Fontas); INSERM U1065, Team 12, C3M, Nice, France (Passeron).

Corresponding Author: Thierry Passeron, MD, PhD, Department of Dermatology, University Hospital of Nice, Archet 2 Hospital, 150 route de Ginestière 06200, Nice, France (passeron@unice.fr).

Published Online: February 25, 2015. doi:10.1001/jamadermatol.2014.5580.

Author Contributions: Drs Passeron and Hammami Ghorbel had full access to all the data in the study and take responsibility for the integrity of the data and the accuracy of the data analysis.

Study concept and design: Hammami Ghorbel, Fontas, Passeron.

Acquisition, analysis, or interpretation of data: Hammami Ghorbel, Boukari, Fontas, Montaudié, Bahadoran, Lacour.

Drafting of the manuscript: Hammami Ghorbel, Boukari, Fontas, Montaudié, Passeron.

Critical revision of the manuscript for important intellectual content: Hammami Ghorbel, Fontas, Bahadoran, Lacour, Passeron.

Statistical analysis: Fontas.

Obtained funding: Hammami Ghorbel, Passeron.

Administrative, technical, or material support: Lacour.

Study supervision: Lacour, Passeron.

Conflict of Interest Disclosures: None reported.

Funding/Support: This study was supported in part by KNS lease.

Role of the Funder/Sponsor: KNS Lease had no role in the design and conduct of the study; collection, management, analysis, and interpretation of the data; preparation, review, or approval of the manuscript; and decision to submit the manuscript for publication.

Trial Registration: clinicaltrials.gov Identifier: NCT01850186

1. Passeron T. Melasma pathogenesis and influencing factors: an overview of the latest research. *J Eur Acad Dermatol Venereol*. 2013;27(suppl 1):5-6.
2. Na JI, Choi SY, Yang SH, Choi HR, Kang HY, Park KC. Effect of tranexamic acid on melasma: a clinical trial with histological evaluation. *J Eur Acad Dermatol Venereol*. 2013;27(8):1035-1039.
3. Passeron T, Fontas E, Kang HY, Bahadoran P, Lacour JP, Ortonne JP. Melasma treatment with pulsed-dye laser and triple combination cream: a prospective, randomized, single-blind, split-face study. *Arch Dermatol*. 2011;147(9):1106-1108.
4. Passeron T. Long-lasting effect of vascular targeted therapy of melasma. *J Am Acad Dermatol*. 2013;69(3):e141-e142.
5. Lee HI, Lim YY, Kim BJ, et al. Clinicopathologic efficacy of copper bromide plus/yellow laser (578 nm with 511 nm) for treatment of melasma in Asian patients. *Dermatol Surg*. 2010;36(6):885-893.
6. Eimpunth S, Wanitphakdeedecha R, Triwongwanat D, Varothai S, Manuskiatti W. Therapeutic outcome of melasma treatment by dual-wavelength (511 and 578 nm) laser in patients with skin phototypes III-V. *Clin Exp Dermatol*. 2014;39(3):292-297.